

## Embolic Central Retinal Artery Occlusion with Spared Cilio-Retinal Artery Caused by Triamcinolone Acetonide Suspension Injection into the Temporomandibular Joint: Case Report and Review of Literature.

Sanjiv Kumar Gupta<sup>1</sup>, Ajai Kumar<sup>2</sup>, Siddhartha Bose<sup>3</sup>, Preeti Singh<sup>4</sup>

### Abstract

We report a case of central retinal artery occlusion after Triamcinolone Acetonide suspension (TMA) injection into Temporomandibular joint (TMJ) and review of relevant literature. *Case description:* A 25-year old male presented with sudden painful vision loss in right eye immediately after TMA injection into right TMJ 24 hours prior to presentation. It was associated with transient dizziness and nausea. At presentation, his vision in the right eye was hand movement and projection of rays full. A complete ophthalmic examination was performed. Anterior segment examination was unremarkable, except for relative afferent pupillary defect in the right eye. Other than that, there was pale edematous retina with marked arteriolar thinning with intra-arterial TMA seen in few of the blocked arterioles and a cherry red spot at the macula. Treatment in form of ocular massage, hyperbaric oxygen therapy and oral Prednisolone (Omnacortil) 1.5mg/ kg as well as topical Difluprednate 0.05% (Diflucor), Bromfenac 0.09% (Unibrom) and Brimonidine 0.1% (Alphagan-P) was instituted, and patient was kept under observation for 1 week and followed up for one month, when the visual recovery was poor with final best corrected visual acuity at 6/60 on Snellen's chart. *Literature review:* Several cases have been reported which show severe irreversible visual loss following intralesional corticosteroid injection in the head and neck area. *Clinical relevance:* Intra-articular injection into the TMJ should be given with caution and informed consent for the same must be taken before the procedure as it may cause irreversible, sight-threatening complication.

**Keywords:** Crao; Central Retinal Artery Occlusion; Triamcinolone Acetonide Suspension; Arterial Embolism; Vision Loss; Vascular Occlusion; Injection Complication.

### Introduction

The central retinal artery (CRA) is a branch of the ophthalmic artery (OA), which is the first branch of the internal carotid artery and it supplies blood to the inner retinal layers [1]. The outer retina is supplied by the chorio-capillaris of the choroid which are supplied by the posterior short ciliary arteries which also originates from the OA [2].

Central retinal artery occlusion (CRAO) which usually occurs due to emboli in the blood circulation is an ophthalmic emergency and the ocular analogue of cerebral stroke [3]. Anatomical studies show that the narrowest part of the CRA lumen is where it pierces the dural sheath of the optic nerve and that this was the most common location where CRAO occurred [4]. A prospective study of 260 eyes with CRAO showed that the subjects have profound monocular irreversible visual loss, with 80% of patients having a final visual acuity (VA) of 20/400 or worse [5].

In few individuals, there may be an anatomical variation, that is, the presence of a cilioretinal artery. It usually supplies the papillo-macular bundle which is essential for central vision. A study on 1000 consecutive patients, using fundus fluorescein angiography (FFA), found a cilioretinal artery to be present in 49.5% of patients [6]. In these

**Author Affiliation:** <sup>1</sup>Professor <sup>3,4</sup>Junior Resident, Department of Ophthalmology, King George's Medical University, Lucknow, Uttar Pradesh 226003, India. <sup>2</sup>Senior Surgeon, Retina unit, Jan Kalyan Eye Hospital, Indira Nagar, Lucknow, Uttar Pradesh 226016, India.

**Corresponding Author:** Sanjiv Kumar Gupta, Department of Ophthalmology King George Medical University, Lucknow, Uttar Pradesh 226013, India.

E-mail: [sanjiv204@gmail.com](mailto:sanjiv204@gmail.com)

Received on 14.06.2018, Accepted on 25.07.2018

patients, the macula may still be perfused in acute CRAO, thus preserving a small island of central vision.

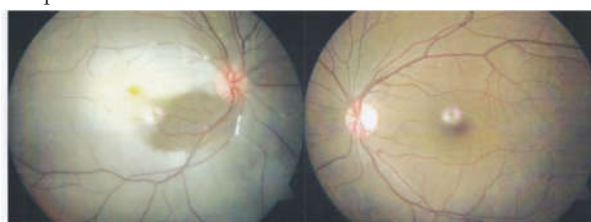Conclusions from studies done on rhesus monkeys show no detectable damage was done with CRAO of 97 min. However, between 105 and 240 min there was a variable degree of partial retinal recovery seen on visual-evoked potential. At 240 min, complete or almost total optic nerve atrophy and nerve fiber damage resulting in massive irreversible retinal damage was found in all eyes. The exact retinal tolerance time when irreversible damage occurs appears to be no longer than 4 hrs [7].

Current options for therapy include the so-called 'standard' therapies, such as sublingual isosorbide dinitrate, systemic pentoxifylline or inhalation of carbogen, hyperbaric oxygen, ocular massage, globe compression, intravenous acetazolamide and mannitol, anterior chamber paracentesis, and methylprednisolone. However, none of these therapies has been shown to be better than placebo [8].

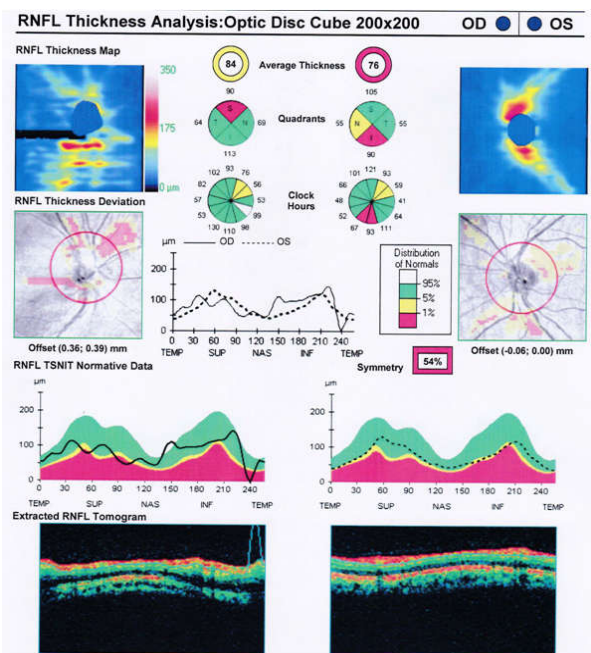
### Case report

A 25-year old young male was referred to us with sudden painful vision loss in his right eye. One day prior to presentation, he had received intra-articular injection of Triamcinolone Acetonide suspension 4% (TMA) into the right temporomandibular joint TMJ for non-infective arthritis (as per his records). Immediately after the injection, he had an episode of dizziness with nausea and inability to see with the right eye. Dizziness and nausea resolved spontaneously but the visual loss persisted. The patient did not give any history of systemic illnesses. When he first visited our clinic, the best corrected visual acuity in the right eye was hand motion and projection of rays full, while the left eye was at 6/6. Anterior and posterior segment examination of left eye was unremarkable while right eye had a relative afferent pupillary defect and on fundus examination of the right eye, the entire retina was pale and edematous retina with marked arteriolar thinning with TMA emboli seen in few blocked arterioles barring a small well perfused area inferior to macula (Figure 1) with a foveal cherry red spot.

The optical coherence tomography (OCT) revealed thickening of the Retinal Nerve Fiber Layer (RNFL), which confirms edema of the retinal tissue (Figure 2). Visual prognosis was explained and despite retinal ischemia time of 4 hours had elapsed, a trial of ocular massage and hyperbaric



**Fig. 1:** Fundus photograph of the subject showing CRAO (Central Retinal Artery Occlusion) with spared cilioretinal artery (red arrow) in the Right eye. Left eye fundus is normal in appearance. Note the TMA emboli in the arterioles (Blue arrows).



**Fig. 2:** Optical coherence tomography (OCT) Retinal Nerve Fiber Layer (RNFL) of the right and left eyes showing edematous retinal tissue in the peripapillary area in the right eye and normal left eye.

oxygen therapy was administered, but there was no change seen in location of impacted emboli or visual status after 24 hours of therapy. A Carotid Artery Doppler to look for the source of embolism was planned but the patient did not consent. Treatment with oral Prednisolone (Omnacortil) 1.5mg/kg body weight, topical Difluprednate 0.05% (Diflucor), Bromfenac 0.09% (Unibrom) and Brimonidine 0.1% (Alphagan-P) was started. Patient was recalled after 1 week and subsequently at 1 month. The visual acuity had minor improvement, with best corrected visual acuity of 6/60 on Snellen's chart attributable to the small area of preserved retina due to the cilio-retinal artery.

## Discussion

There have been few single case reports of this type of embolization of retinal arterial circulation caused by accidental injection of TMA suspension into adjacent arterial blood vessels. Similar incident of central retinal artery occlusion has been reported with severe vision loss after intra-articular injection of TMA suspension into TMJ and maxillary soft tissue [9,10]. There was no improvement in vision despite treatment in both case reports.

Embolization of retinal and choroidal arterial circulation has been reported during orbital injection of TMA for thyroid-associated ophthalmopathy [11]. They have reported limited visual gain after immediate aggressive therapy with oxygen supplementation and vasodilator therapy. Similarly, a posterior sub-tenon injection caused not only CRAO due to TMA emboli in arterial circulation but was also accompanied with retro-bulbar hemorrhage and severe ipsilateral vision loss with limited recovery at one month [12].

Subcutaneous triamcinolone acetonide steroid injection at the site of a keloid on the left earlobe caused temporary left-sided facial numbness, diaphoresis, dizziness, hypoesthesia of the left side of the mouth and tongue, left upper lid ptosis, and nearly complete vision loss in left eye in a patient with complete recovery after several hours. Though, they have not described the findings of the retinal circulation and fundus findings [13]. Sever irreversible bilateral CRAO has been reported due to forehead intradermal injection of TMA suspension for treatment of cosmetic skin lesion [14,15].

Intra oral injection of TMA in submucosal fibrous scar in the left mandibular retromolar pad has been reported to cause ipsilateral multiple Branch Retinal Occlusions and ocular ischemic syndrome due to involvement of anterior and posterior choroidal circulation also [16]. The visual recovery was reported to be poor after one month after the event. Similar occlusion of retinal and choroidal arterial circulation and subsequent severe irreversible vision loss and retinal atrophy has been reported after TMA injection in nasal mucosa and nasal concha [17,18].

## Conclusions

Injection of TMA suspension in the region of head and neck should be done judiciously with informed consent regarding complications which can occur as per the available case reports. Arrangement should be there to manage any such situation

which may arise due to accidental intraarterial injection, including vasodilators (Nitroglycerine, Carbogen (95% oxygen and 5% Carbondioxide)), ocular massage and paracentesis to minimize the damage. During the procedure adequate suction should be created in the suction before injecting the suspension to make sure that there is no blood drawn in the syringe. This will confirm that the syringe is not in intravascular space. The injection speed should be slow and with low pressure. After the injection has been administered, patient should be kept under observation for a while before sending the patient away.

*Conflict of Interest:* No potential conflict of interest relevant to this article was reported.

*Acknowledgments:* None

## References

1. Singh S, Dass R. The central artery of the retina I. Origin and course. *Br J Ophthalmol* 1960;44: 193.
2. Hayreh SS. Acute retinal arterial occlusive disorders. *Prog Retin Eye Res* 2011;30:359-94.
3. DD Varma, S Cugati, AW Lee and CS Chen. A review of central retinal artery occlusion: clinical presentation and management. *Eye* 2013;27:688-97.
4. Hayreh S. Pathogenesis of occlusion of the central retinal vessels. *Am J Ophthalmol* 1971; 72:998.
5. Hayreh SS, Zimmerman MB. Central retinal artery occlusion: visual outcome. *Am J Ophthalmol* 2005;140(3):376-91.
6. Justice Jr J, Lehmann RP. Cilioretinal arteries: a study based on review of stereo fundus photographs and fluorescein angiographic findings. *Arch Ophthalmol* 1976;94:1355.
7. Hayreh SS, Zimmerman MB, Kimura A, Sanon A. Central retinal artery occlusion. Retinal survival time. *Exp Eye Res* 2004;78:723-36.
8. Fraser SG, Adams W. Interventions for acute non-arteritic central retinal artery occlusion. *Cochrane Database Syst Rev* 2009; 1: CD001989.
9. Nripen Gaur, Pallavi Singh, Rohan Chawla, Brijesh Takkar. Triamcinolone emboli leading to central retinal artery occlusion: a multimodal imaging study. *BMJ Case Reports* 2017; published online 22 February 2017, doi:10.1136/bcr-2016-218908.
10. Nianiaris NA, Mandelcorn M, Baker G. Retinal and choroidal embolization following soft-tissue maxillary injection of corticosteroids. *Can J Ophthalmol*. 1995 Oct;30(6):321-3. PubMed PMID: 8574981.
11. Li G, Xu D, Hu Z, Li H. Embolic retinal and choroidal vascular occlusion after peribulbar triamcinolone injection: A case report. *NA.*,

- ed. *Medicine*. 2018;97(17):e0467. doi:10.1097/MD.00000000000010467.
12. Moshfeghi DM, Lowder CY, Roth DB, Kaiser PK. Retinal and choroidal vascular occlusion after posterior sub-tenon triamcinolone injection. *Am J Ophthalmol*. 2002 Jul;134(1):132-4. PubMed PMID: 12095826.
  13. Chavala SH, Williamson JF, Postel EA. Embolic central retinal artery occlusion after subcutaneous auricular steroid injection. *Lancet*. 2016 May 28;387(10034):2235. doi: 10.1016/S0140-6736(15)00980-0.
  14. Liu OG, Chunming L, Juanjuan W, Xiaoyan X. Central retinal artery occlusion and cerebral infarction following forehead injection with a corticosteroid suspension for vitiligo. *Indian J Dermatol Venereol Leprol*. 2014 Mar-Apr;80(2):177-9. doi: 10.4103/0378-6323.129416.
  15. Edwards AO. Central retinal artery occlusion following forehead injection with a corticosteroid suspension. *Pediatr Dermatol* 2008;25:460-1.
  16. McEwan G, Hofmeister E, Kubis K, Blade K. Monocular embolic retinal arteriolar occlusions after ipsilateral intraoral triamcinolone injection. *J Neuroophthalmol*. 2010 Mar;30(1):98-9. doi: 10.1097/WNO.0b013e3181ce8048. PubMed PMID: 20182219.
  17. Hirata A, Kubo M, Okinami S. Severe retinal atrophy due to retinal and choroidal vascular occlusion following triamcinolone injection into the nasal mucosa. *Jpn J Ophthalmol*. 2008 Nov-Dec;52(6):510-511. doi: 10.1007/s10384-008-0596-9. Epub 2008 Dec 17. PubMed PMID: 19089579.
  18. Martin PA, Church CA, Petti GH Jr, Hedayi R. Visual loss after intraturbinate steroid injection. *Otolaryngol Head Neck Surg*. 2003 Feb;128(2):280-1. PubMed PMID: 12601327.
-